

Cryptococcosis presenting as eruptive xanthomata, reveals diagnosis of HIV/AIDS

Emory University School of Medicine, Dermatology
Adrianna Rodriguez, MD
Sareeta Parker, MD

Georgia Society of Dermatologists
Resident Symposium
June 2011

Financial Disclosures

- None



History

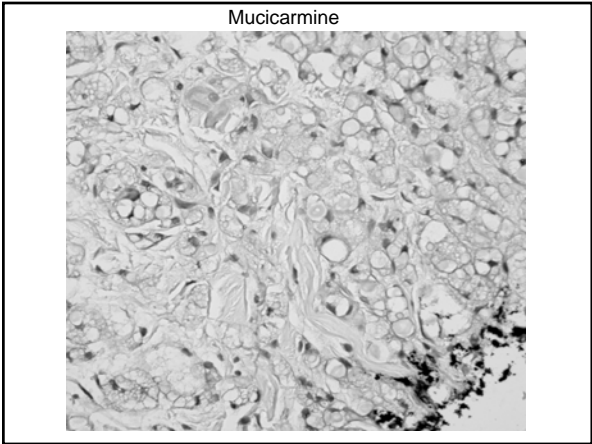
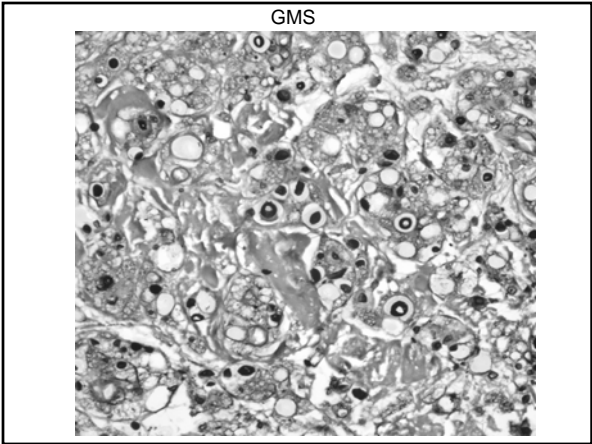
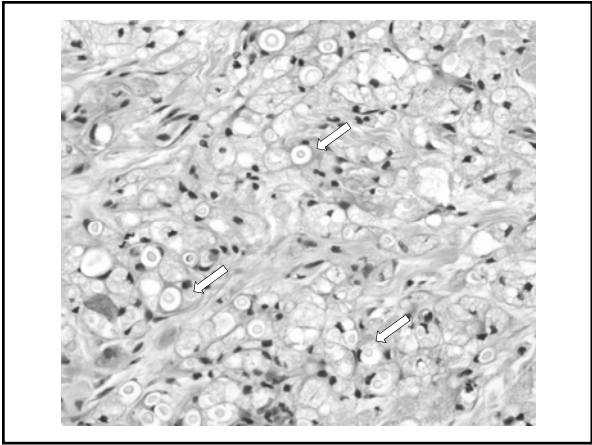
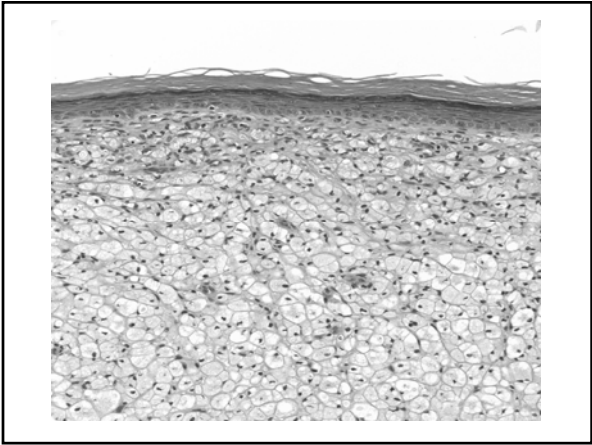
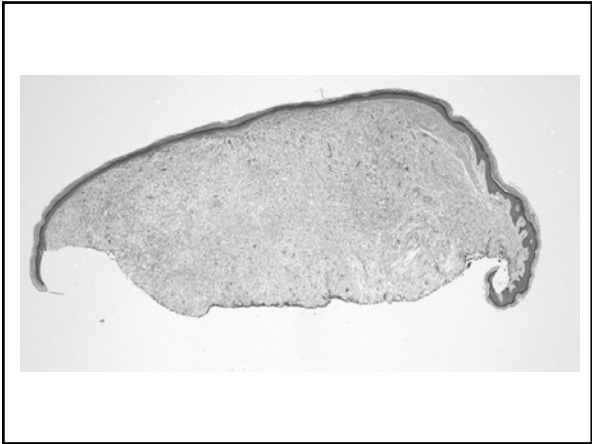
- PMH: none
- MEDS: none
- SH: homosexual
- ROS: no fevers/chills/weight loss, headaches

Differential Diagnosis

Differential Diagnosis

- Xanthomata
- Molluscum Contagiosum
- Sarcoidosis
- Adnexal tumors

Biopsy



Course

- Labs:
 - Serologic evaluation was positive for HIV
 - CD4 count was 13 cells/mm³
 - Lipid profile was normal
- Hospital Course:
 - Cryptococcal ag titer was positive
 - » Serum (>1:514)
 - » CSF (>1:514)

Disseminated Cryptococcosis

Cryptococcal
Meningitis

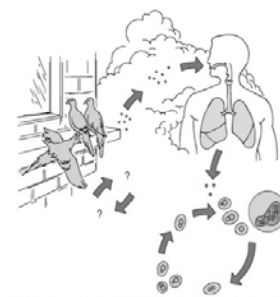
2° Cutaneous
Cryptococcosis

Cryptococcosis

- Opportunistic, yeast-like fungus
- Saprophyte of soil, pigeon droppings
- Highest risk factor is AIDS (50%)
 - * can affect immunocompetent hosts

Cryptococcosis

- Aerosolized inhalation to lungs (1° site)
- Most commonly spreads to:
 - CNS
 - Skin (10% in AIDS)
 - Eyes
 - Bone
 - Prostate



© Elsevier, Murray: Medical Microbiology 5e - www.studentconsult.com

Dermatology

Case Report

Dermatology 2002;20(4):145-149

Received June 1, 2001

Accepted July 20, 2001

Primary Cutaneous Cryptococcosis in an Immunocompetent Host: Case Report and Review of the Literature

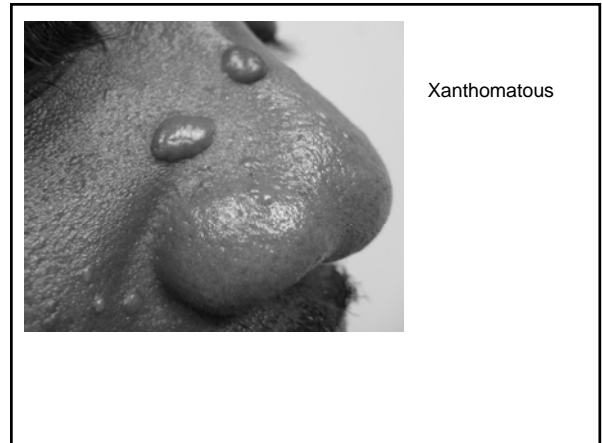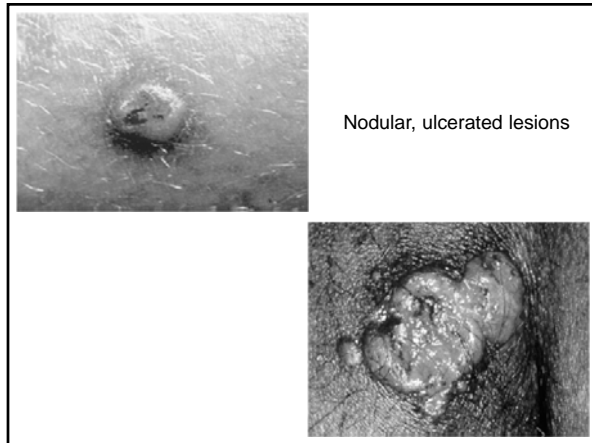
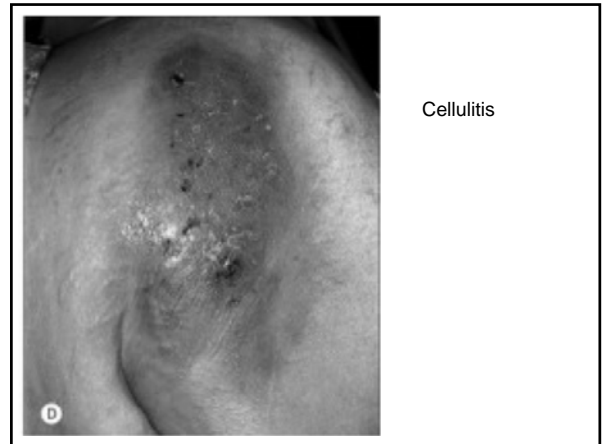
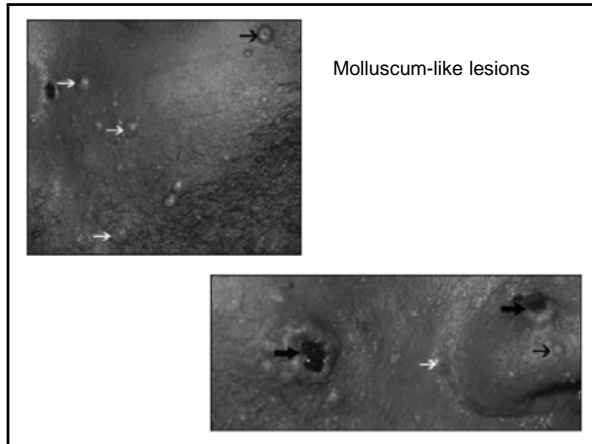
F. Revenga* J.F. Paricio* F.J. Merino^b T. Nebreda^b T. Ramirez^c A.M. Martinez*

*Unit of Dermatology, ^bSection of Microbiology, and ^cDepartment of Pathology, Hospital General de Eorla, Spain

- Primary cutaneous cryptococcosis via percutaneous inoculation is rare
- Few case reports

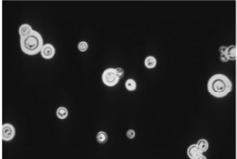
Cryptococcosis

- Clinical Presentation is variable



Cryptococcosis

- Morphology:
 - Spheroid (2-20um)
 - Gelatinous capsule
 - Narrow-based budding
- Stains:
 - GMS, Fontana-Masson, PAS – organism
 - Mucicarmine, Alcian blue, India Ink - capsule



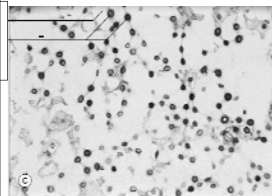
Elsevier, Murray, Medical Microbiology 5e

Cryptococcosis

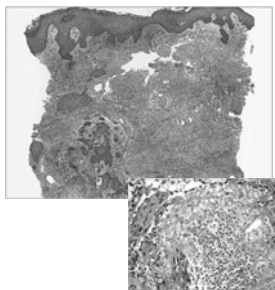
- Histology is variable

Cryptococcosis

Gelatinous pattern



Granulomatous pattern



Case Continued:


- Patient was treated with IV amphotericin B and flucytosine x 2 weeks, then fluconazole 400mg daily
- He has had slow improvement in skin lesions, without complete resolution

Key Points:

- Cutaneous cryptococcosis has a variable clinical and histologic presentation
 - Our case -> xanthomatous
- Cutaneous cryptococcosis occurs almost exclusively in the setting of disseminated disease and immunosuppression
- Even in the absence of systemic symptoms, workup for disseminated disease and HIV is crucial

Thank You!

- Dr. Sareeta Parker
- Dr. Douglas Parker
- Dr. Benjamin Stoff
- Dr. Robert Swerlick



References

- Bolognia et al. 2008. *Dermatology*. 2nd Edition, Elsevier.
- Kasper et al. 2005. *Harrison's Principles of Internal Medicine*. 16th Edition, McGraw Hill.
- Rapini et al. 2005. *Practical Dermatology*. 1st Edition, Elsevier.
- Murray et al. 2005. *Medical Microbiology*. 5th Edition, Elsevier.
- Patel, NC. 2009. Disseminated *Cryptococcus Neoformans*: Case report and review of the Literature. *Cutis* 84(2): 93-96.
- Abuav, R. 2010. Cryptococcal Panniculitis in an Immunocompromised Patient: Case report and review of the literature. *Cutis* 85: 302-306
- Revenge, F. 2002. Primary Cutaneous Cryptococcosis in an Immunocompetent Host: Case Report and Review of the Literature. *Dermatology* 204(2): 145-49.
- Mycology Online. 2011. University of Adelaide, Australia.